

Actual Examples of Improvement of Functions in Patients With Cerebral Central Nervous Diseases in Clinical Practice and the Effects of Kinesio Taping

Yoshiaki Sanada

Director and president of Shimonoseki Chiropractic Laboratory

Kiyotaka Miyano

Department of Rehabilitation, Shimonoseki City Hospital

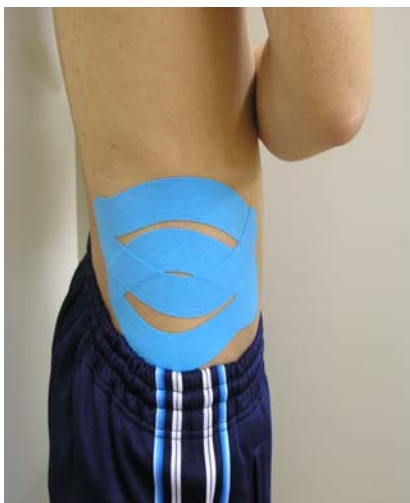Summary: An approach of Kinesio taping for patients with cephalic central diseases showing delayed recovery of functions and patients showing improved functions.

Emphasis of Presentation: Actual examples of taping useful for improvement of chronic symptoms in clinical practice.

Clinical research report or Basic research report:

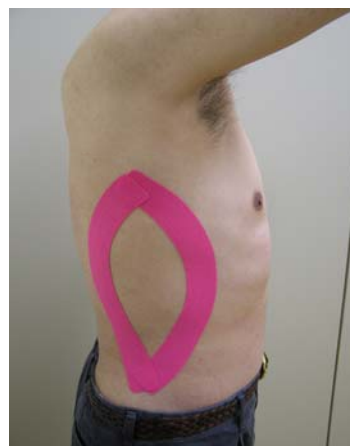In the patients showing delayed recovery of functions in the course of treatment (including rehabilitation) of central nervous system diseases such as cerebral infarction, I studied the changes in the body caused clinically by Kinesio Taping in 3 or 4 patients.

I will not only trace the symptoms but also observe the patients from different standpoints and will present the actual conditions of the effects of Kinesio taping on the body functions that have not been explained through trial and error.

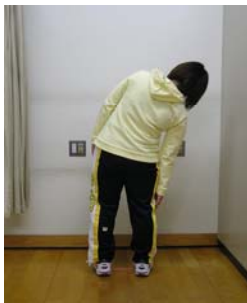
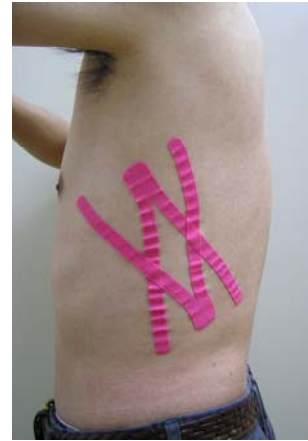
In this study, the taping presented in the panel discussion of the 18th Academic Congress of Kinesio Taping 2 years ago was used, and I will report on the tape and its efficacy. This photograph shows the tape introduced at the 18th congress. As shown in this photograph, a Y-shaped tape of 5 cm in width is attached to the area from the lower part of lower rib to the upper edge of iliac crest without adding any tension. When this tape was applied in patients with cerebral infarction or fracture of upper or lower limbs, who were attending the outpatient clinic of this hospital, improvement of side flexion in the upright position, rotating functions and elevation of the upper limbs and changes in the center of gravity between the right and left sides of body in the upright position were observed. In addition, the change in the posture could be confirmed with static images and photographs. Since I examined the effects when the shape and the attachment site of this tape were changed, I will introduce them with actual examples. I tried 2 shapes of the tape.

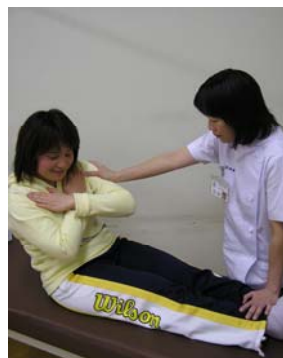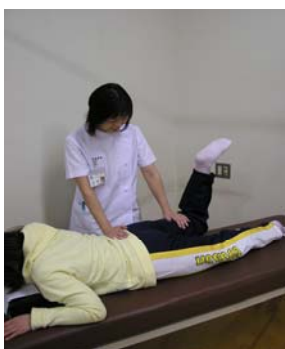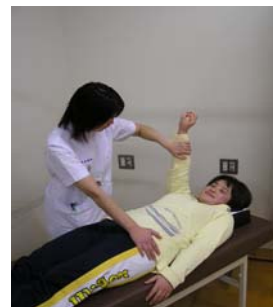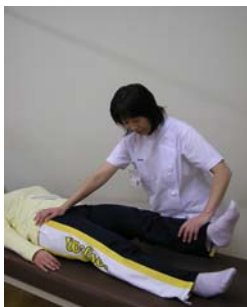<<Tape 1>> Two I-shaped tapes of 3.75 cm in width and 30 cm in length were used. They were attached to the lateral side of the trunk so that the body was rotated to the opposite side and the area from the lower part of the axilla to the lower ribs might be enclosed without adding any tension. This is the O-tape.



<<Tape 2>> Two Y-shaped tapes of 2.5 cm in width and 20 cm in length were used. They were attached to the space from the lower part of the axilla to the lower ribs on the lateral side of the trunk in a direction perpendicular to ribs without adding any tension. This is the V-II tape.



The subject is a patient attending the outpatient clinic of this hospital for rehabilitation. The changes in the postures at side flexion in the upright position, rotation, forward flexion and elevation of the upper limbs were compared before application of Kinesio Tape and immediately after application with static images (photographs).

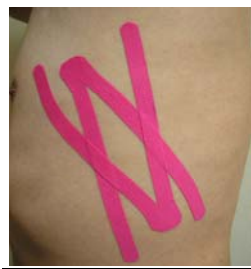

In addition, I asked the patients about muscle strength, pain and changes in activities of daily life. I will introduce 4 cases.

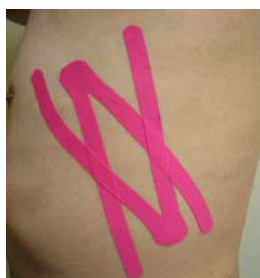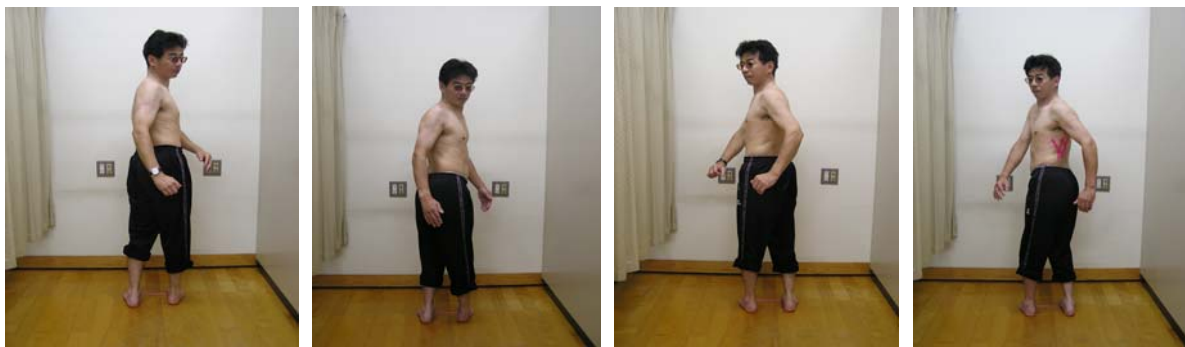Case 1. A 45-year old man, with severe cerebral contusion, traumatic subarachnoid hemorrhage, fracture of lower thigh on both sides (osteosynthesis conducted on November 10, 2002)

November 3, 2002: He was hit by a car while walking and transported into the critical care center of this hospital. He had cerebral contusions, fracture of lower thigh on both sides and severe consciousness disorder.

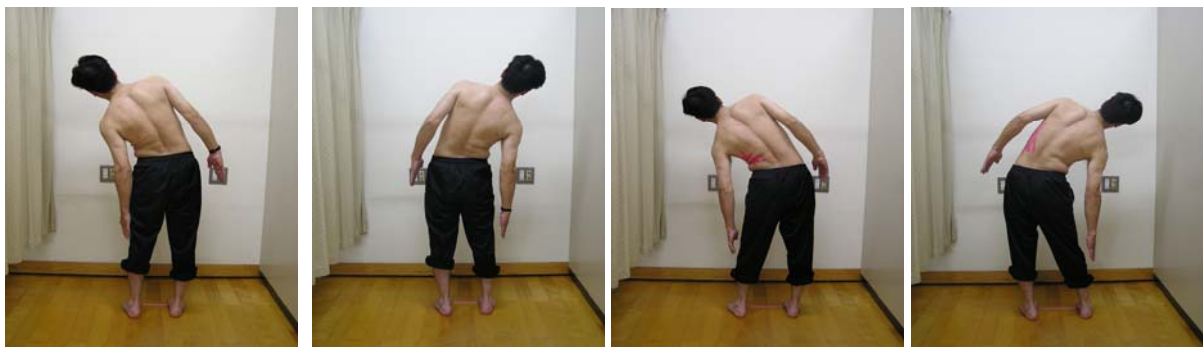November 19, Physical therapy was started at the ICU. His level of consciousness recovered gradually, and when the patient reached the level of assisted walking, he was transferred to another hospital in March 2003. Thereafter, he was transferred repeatedly to other hospitals for the purpose of rehabilitation and has attended the outpatient clinic of this hospital for rehabilitation since May 2004 (2 or 3 times/week). As of November 2004, he could walk independently (he does not fall but makes a false step frequently). He felt numbness in the lower thighs on both sides. Increased tendon reflexes, positive ankle clonus on both sides, limited dorsal flexion in the right ankle joint and lumbago were observed. The right and left muscle level were 4, right < left. Kinesio Taping has been applied since November 20, 2004.



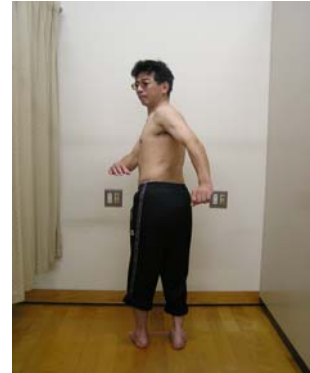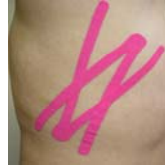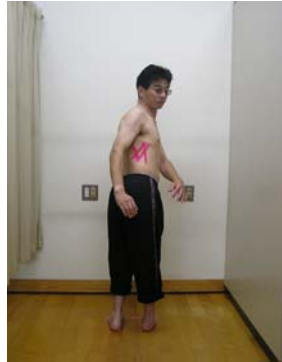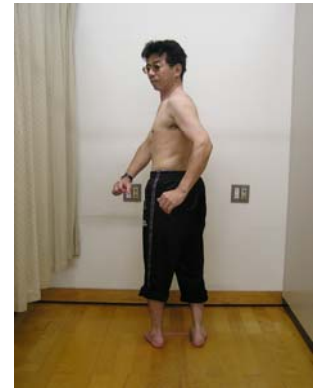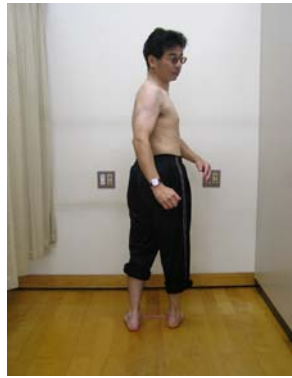The V-II tape was attached to the left side. Rotation in the upright position was improved on both sides.



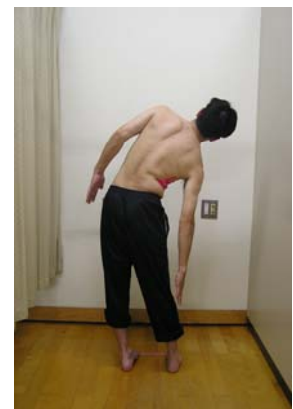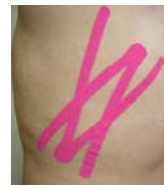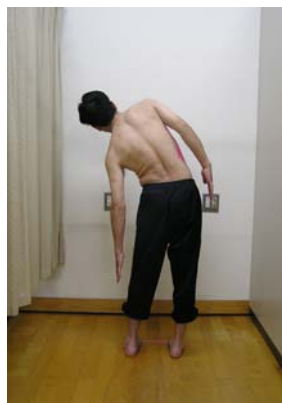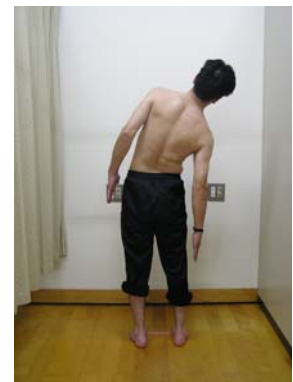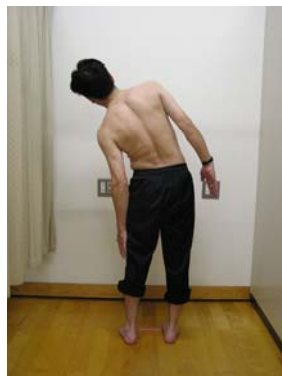Side flexion in the upright position. Lateral transfer of pelvis became smooth, and the curve of the spinal column is also clearly seen



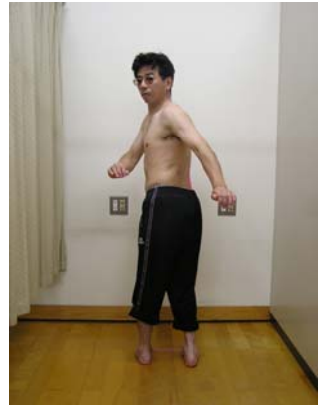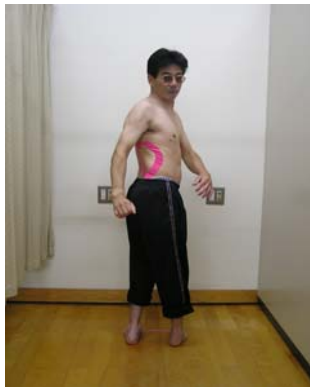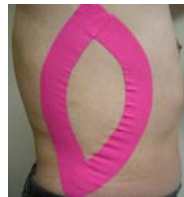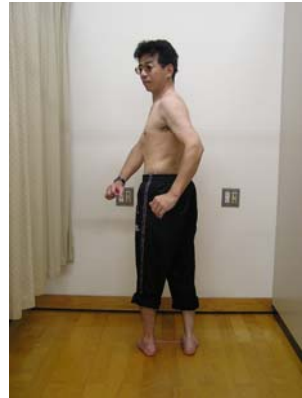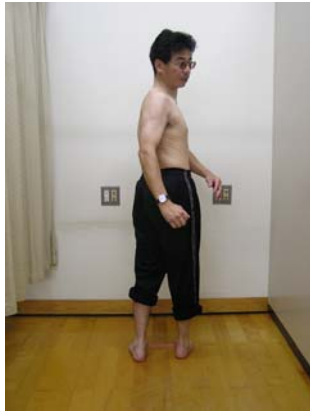The V-II tape was attached to the right side. It showed a tendency toward improvement, but the attachment to the left side is considered to be slightly better.



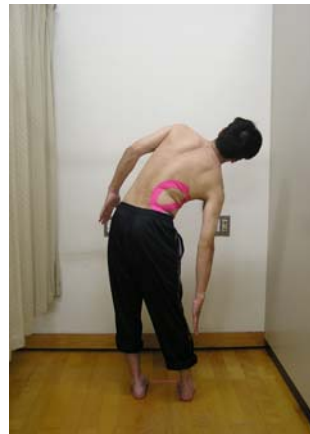
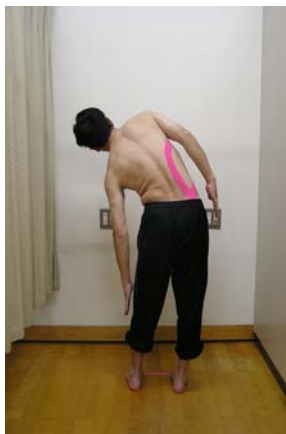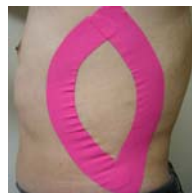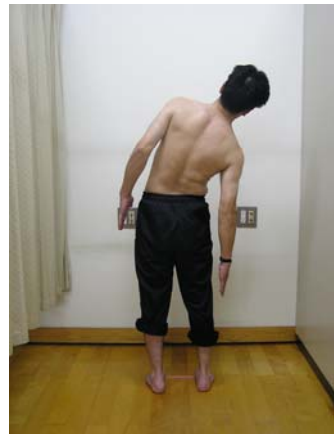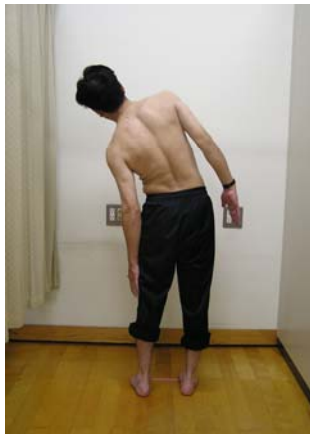As shown previously, the transfer of pelvis was conducted well, and the movement of side flexion was improved.

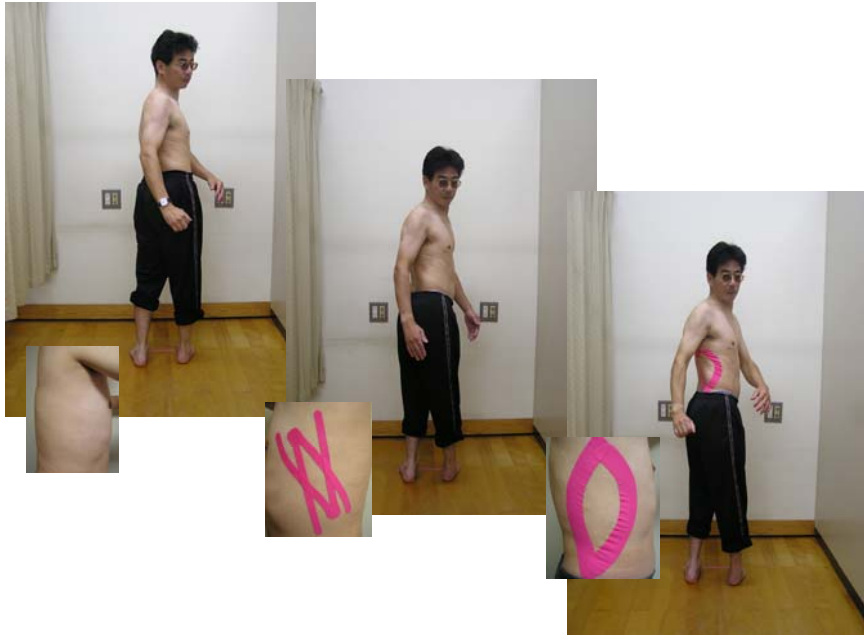

The O-tape was attached to the right side. The effectiveness of Kinesio Tape appeared good.




Lateral transfer of pelvis was also conducted well





From left to right, the photograph showing no attachment of tape, that showing attachment of the V-II tape on the left side and that showing attachment of the O-tape on the right side were compared. For rotation in this case, the O-tape attached to the right side was the most effective.



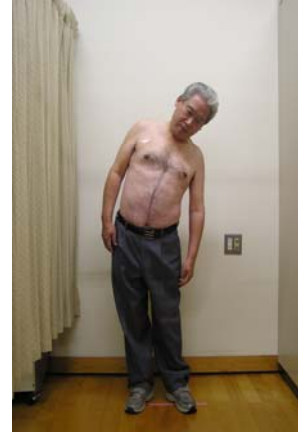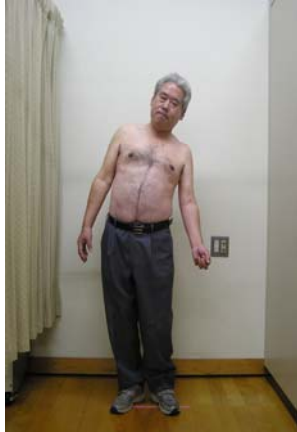This slide shows elevation of upper limbs in the upright position. When no Kinesio Tape is attached, the center of gravity transferred forward, and the patient generally showed the anteverted position. In the photograph on the right, the patient elevated upper limbs with the Kinesio Tape attached. The center of gravity was stabilized, and the anteverted position was corrected.

Summary of Case 1

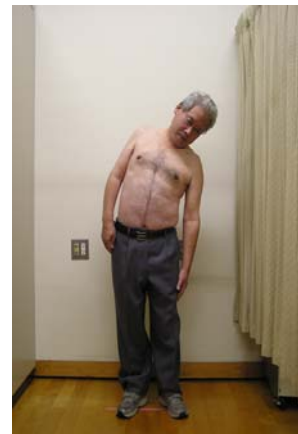
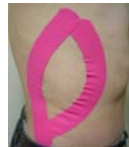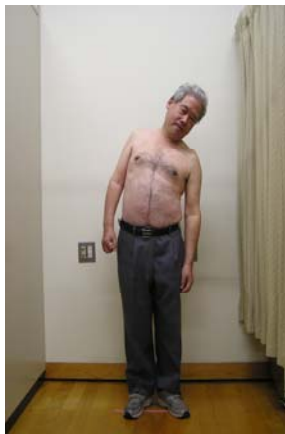- Functional improvement was observed in side flexion in the upright position, rotation and elevation of upper limbs. For rotation, the O-tape showed good results.
- Muscle strength on both sides increased in the upper limbs, lower limbs and trunk.
- The anteverted position at standing was reduced.
- The patient could ascend the stairs smoothly.
- Lumbago was reduced.

Case 2. A 69-year old man with right cerebral infarction and left hemiplegia. He showed the symptoms on June 29, 2000, and he was transported to this hospital. Physical therapy was started on July 3. He could walk using a cane, and he was discharged from hospital on August 17. Thereafter, he has attended the outpatient clinic in this hospital (twice/week). As of November 2004, he could stand up and walk using a cane (he may make a false step frequently). When he walked for about 20 minutes, lumbago and buttock pain appeared. He could not stand on one foot on the paralyzed side. He has difficulty in walking on a slope (downward). The upper limbs on the paralyzed side required assistance. Kinesio Taping has been applied since November 26, 2004.

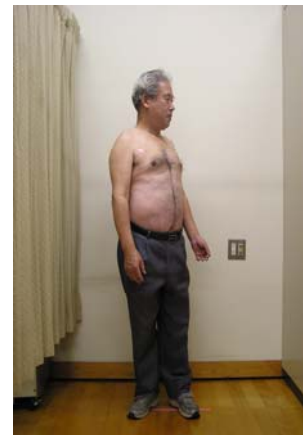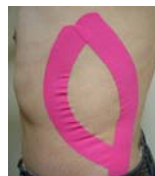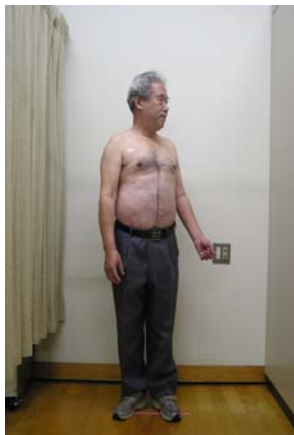The O-tape was attached to the left side (paralyzed side). The tension in the left upper limbs was reduced, and expression and side flexing action were improved.



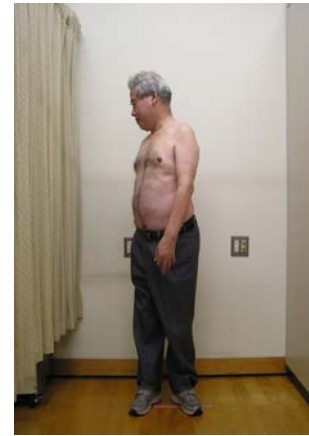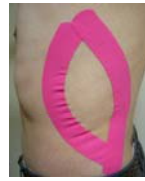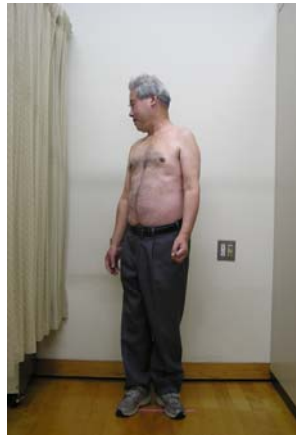Similar improvement was observed



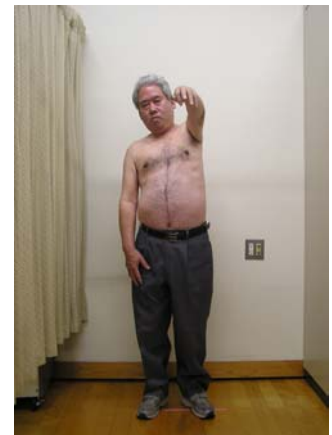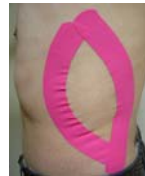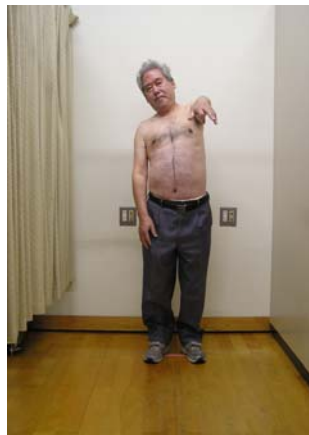Rotation in the upright position. He could rotate his body to the left (paralyzed side) easily



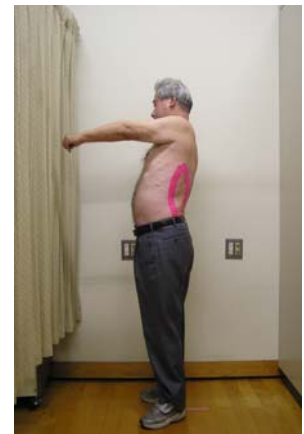
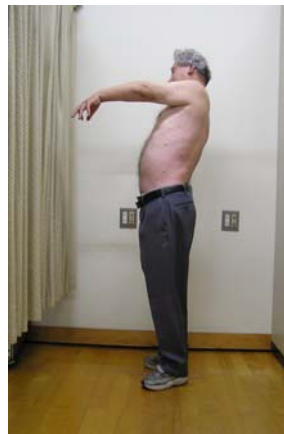As seen from hands and fingers, the tension on the paralyzed side was removed, and he could rotate easily.



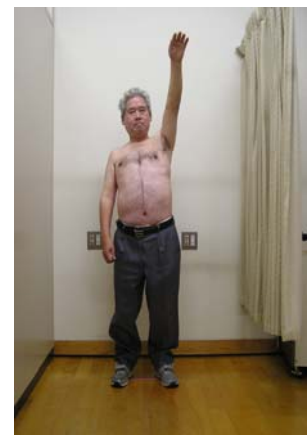
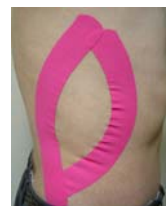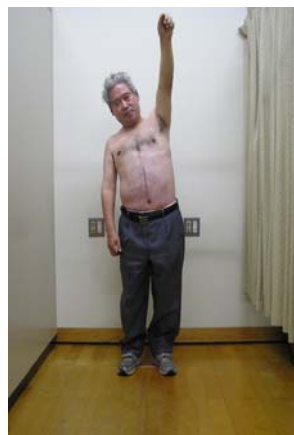Elevation of the upper limbs on the paralyzed side. Marked compensation of the trunk was observed without the tape, but the compensating action decreased and the angle of elevation increased after application of Kinesio Tape



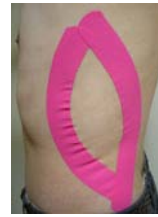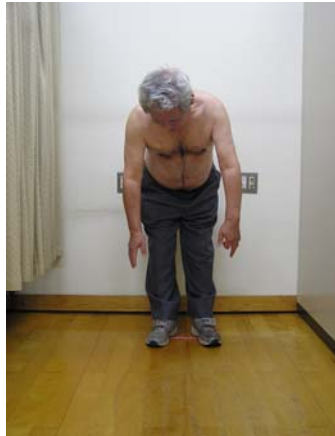This is a photograph taken from the lateral side. Apparently, the upper limbs could be elevated to the horizontal level, but it was confirmed that the stretching of the trunk decreased



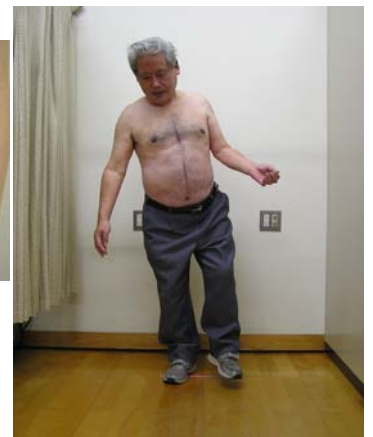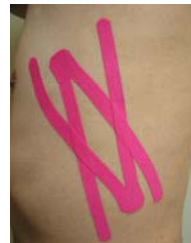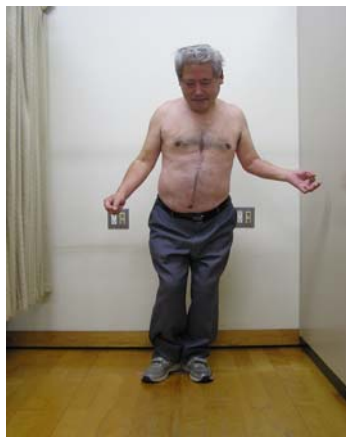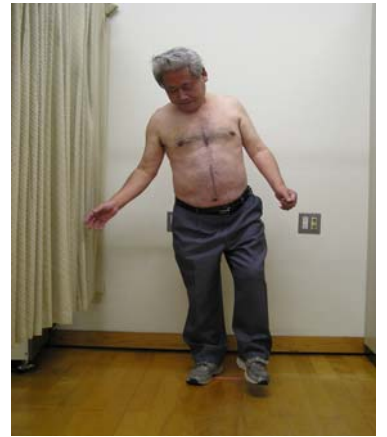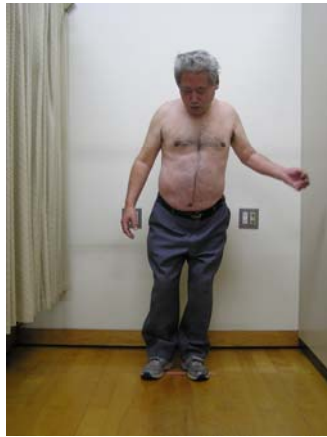Elevation on the non-paralyzed side. In the absence of the Kinesio Tape, he elevated the upper limbs while slanting the trunk and head, but on the side with the tape attached, he could elevate the upper limbs with the head and trunk at almost the median position.



Forward flexing action in the upright position. In comparison with the photograph without tape, the angle of forward flexing increased clearly. In addition, the torsion of the head and trunk at the time of action was also improved.



A photograph of the patient standing on one foot. The photograph on the left shows the support on the left (paralyzed) side. The sole of foot scarcely came off from the floor without the Kinesio Tape, but if the tape was attached, he could lift his leg slightly from the floor (since this photograph could not capture the moment well, the lifting from the floor could not be confirmed). The photograph on the right shows the support on the right (non-paralyzed) side. Apparently, the lifting of his foot seemed to be similar, but when Kinesio tape was applied, the timing and action of lifting up the leg became smooth.

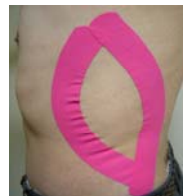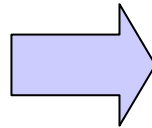


Summary of Case 2

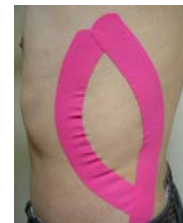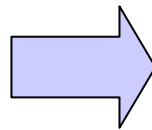
- Functional improvement was observed in side flexion in the upright position, rotation, forward flexion and elevation of upper limbs.
- Standing on one foot on the paralyzed side became slightly possible.
- Muscle strength on both sides increased in the upper limbs, lower limbs and trunk.
- Lumbago in walking was reduced.
- False steps decreased.

Case 3. A 69-year old woman with meningioma in the left tentorium cerebelli. On April 26, 2004, a craniotomized total enucleation of a tumor was conducted. Postoperatively, autokinetic motion in the right upper limb was bad, and numbness in the right upper limb was observed. On April 30, physical therapy was started. She used a walker in May but could walk independently in June. She elevated the right upper limb to the angle of 60°. She was discharged from hospital on September 3. Thereafter, she has attended the outpatient clinic of this hospital for rehabilitation (once/week). As of October 2004, she had neck pain and lumbago (right < left), difficulty in elevation of the right upper limb, numbness in the upper limbs at night and awoke frequently. Kinesio Tape has been applied since October 29, 2004.

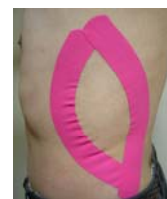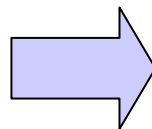
The O-tape was attached to the left side. Side flexion in the upright position. In comparison with the stance without Kinesio Taping, lateral transfer to the opposite side could be done well



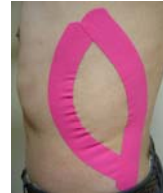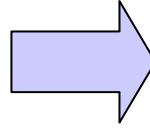

Side flexion to the right side. As seen on the left side, lateral transfer of the pelvis and flexibility of the lateral side of the trunk were improved.



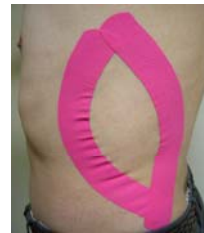In the rotation to the left side in the upright position, rotation became easy as she could turn around to the rear side.



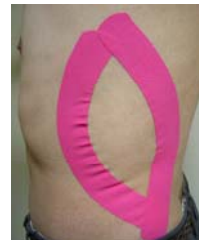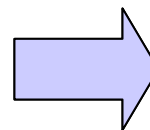
Not as good as the rotation to the left side, but improvement was observed



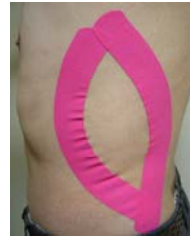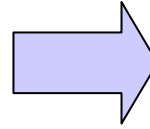
Forward flexion in the upright position. Backward transfer of pelvis was good on both sides, but the side with the Kinesio tape attached showed the curve of the spinal column clearly. In addition, it could be confirmed that the orientation of the face at forward flexion became straight.



The photograph of elevation of the right upper limb taken from the front. The angle of bending of shoulder increased.



A photograph taken from the side. She could elevate the right upper limb easily to this angle.



The lower photographs show the patient 1 month after the application of Kinesio Tape. Marked improvement was observed.



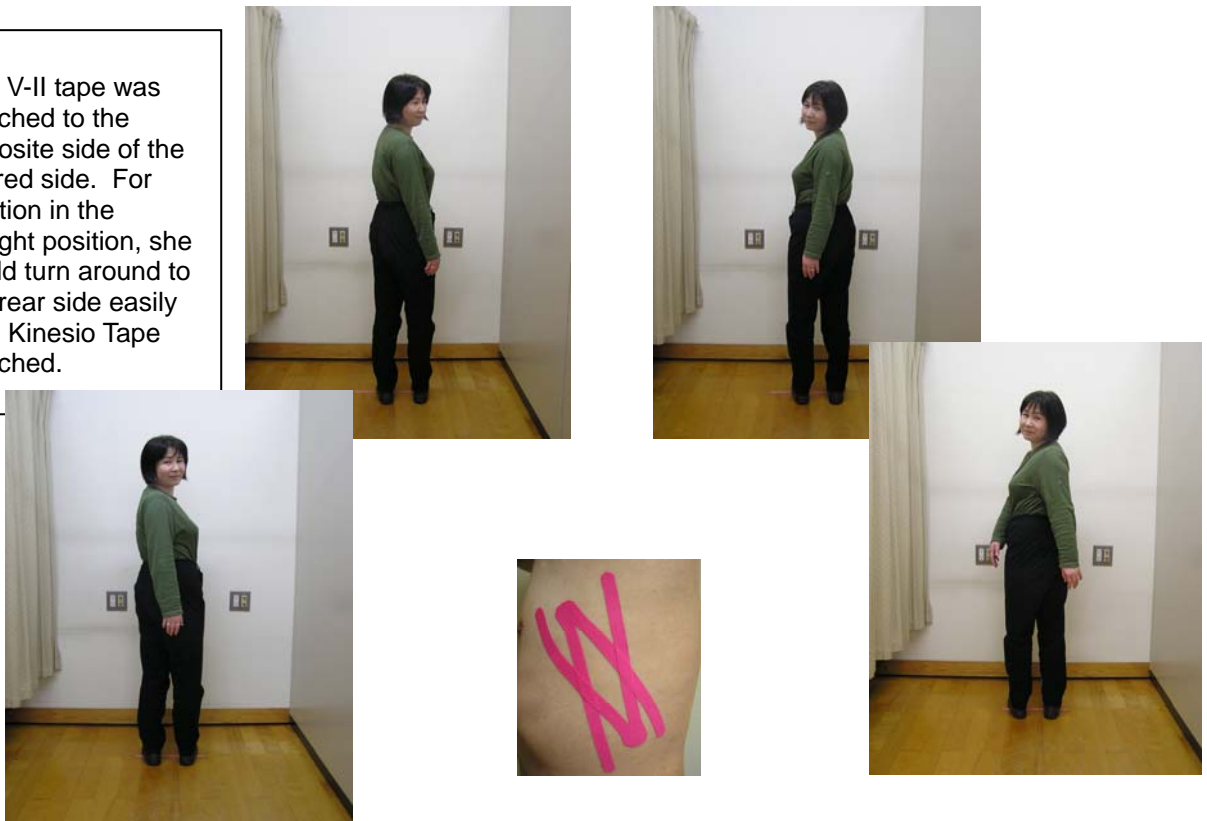
Summary of Case 3

- Improvement was observed in side flexion in the upright position, rotation, forward flexion and elevation of upper limbs.
- Muscle strength on both sides increased in the upper limbs, lower limbs and trunk.
- Lumbago was reduced.
- Numbness at night tended to be reduced.


Case 4. A 45-year old woman with a fracture of the right upper forelimb bone (osteosynthesis on December 22, 2003)

On December 14, 2003, while she was sitting in the front passenger seat of a car, she was injured in a car crash. On December 25, physical therapy was started. The therapy was focused mainly on training for improvement of range of motion. She was discharged from the hospital on January 10, 2004. Thereafter, she has attended the outpatient clinic of this hospital for rehabilitation (2 to 3 times/week). As of November 2004, she had pain around the right shoulder joint and right lumbago. Marked contracture of the shoulder joint was observed, and the right upper limb could be elevated to 130° passively and to 90° independently. She experienced difficulty in washing her hair, bathing, and putting on slacks. Kinesio Taping has been applied since November 12, 2004.

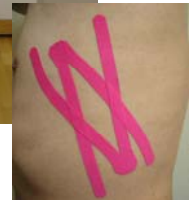The V-II tape was attached to the opposite side of the injured side. For rotation in the upright position, she could turn around to the rear side easily with Kinesio Tape attached.



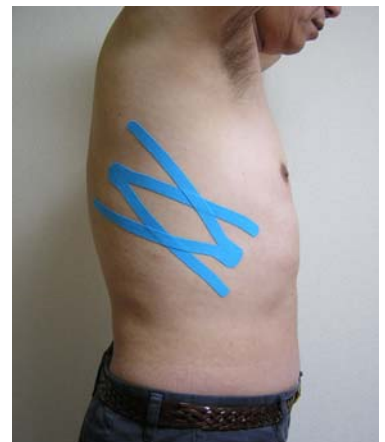In doing side flexion in the upright position, she complained of right lumbago without the Kinesio Tape attached, but even though the tape was attached to the opposite side, the pain disappeared immediately after application.



Elevation of the upper limbs. The angle of elevation was improved slightly, but she could elevate the upper limbs without pain in the shoulder, and she had more strength.



When the V-II tape was attached by changing the direction of attachment of the Kinesio Tape on the right side of the injured side (parallel to the ribs), elevation became easier.



Summary of Case 4

- Improvement was observed in side flexion in the upright position, rotation and elevation of the upper limbs.
- Muscle strength on both sides increased in the upper limbs, lower limbs and trunk.
- Pain around the shoulder and lumbago were reduced.
- Putting on and taking off slacks became easier.
- Kitchen work became easier.
- When the direction of attachment of the V-II tape was changed, the efficacy increased.

Conclusion

- Two types of Kinesio Taping, O-tape and V-II tape were introduced.
- By attaching these tapes to the lateral side of the trunk, effects on normalization of muscular tension, reduction of pain, systemic compound movement and body balance were observed.
- For muscle strength, the efficacy of O-tape and V-II tape appeared in the whole body, and timely muscular contraction was confirmed. That is, near normal responses were observed.
- In the rotating action in the upright position, the O-tape is more effective than the V-II tape.
- Efficacy was observed in the functional improvement in the patients in the chronic phase, and we obtained comments that the physicians could work on the future rehabilitation more actively.
- By combining the Kinesio Tape techniques introduced at this time with the techniques used on other sites, further efficacy can be expected.
- We again realized the importance of functional improvement of impaired sites other than the injured sites and the necessity to have a perspective for grasping the entire range of movements.

The staff of this hospital cooperating for this presentation.

