

Kinesio Taping for Skin Wounds

Kiyotaka Oka

Office Ikuno, President

Summary: Kinesio Tape was used on skin wounds such as burns, abrasions and incised wounds to examine its effects on the recovery rate of skin wounds.

Emphasis of Presentation: The wounds heal cleanly and rapidly by applying a moistened Kinesio Tape to the edge of wound.

Clinical research report or Basic research report:

Usually, Kinesio Tape is used for joint pain and muscle pain, but in this study, Kinesio Tape was used for the treatment of skin wounds as a new use of Kinesio Tape.

Method: Moistened or dry Kinesio Tape was applied to wounds such as burns, abrasions and incised wounds and the results compared compared.

Results: It was found that wounds healed rapidly and cleanly by using Kinesio Tape while maintaining moist conditions. In addition, it was well received by patients who felt the wounds healed rapidly and cleanly.


Discussion: It is believed that the rate of skin cell regeneration can be improved by increasing the circulation of blood and lymph fluid, which is facilitated by use of moistened Kinesio Tape. The natural healing power is maximized with Kinesio Tape and the regeneration of skin is accelerated and the wound heals rapidly and cleanly.

We usually use Kinesio Tape for joint pain and muscle pain, but even when the injury is treated by using adhesive Tape, healing is often delayed and scars remain, so my family and I examined whether Kinesio Tape can be used for the treatment of skin injury.

I read a newspaper article that said, "Skin injuries heal more quickly and finely by treating without drying and while keeping moist." In an orthopedic clinic, skin injuries heal cleanly and quickly by using wound coverings and keeping the area moist. Recently, adhesive Tapes for injury using coverings have been marketed, but as a Kinesio Tape lover, I treated the skin wound using Kinesio Tape, keeping it moist by use of tap water and deep sea water (for skin care). In addition, in a few cases, we compared the healing rate between a case left dry without attaching anything and a case using the usual adhesive Tape.

<Methods>

1. The wound should be washed with tap water. No disinfectant should be used. This is because, as it was described in the newspaper, "Not only bacteria but also living cells (white blood cells, fibroblasts, epidermal cells, etc.) may be killed by using disinfectants, and as a result, infections are induced and wound healing is delayed." However, if foreign matter such as sand or glass pieces entered the wound, they can cause purulence, so they should be removed completely by brushing. It may be necessary to remove any deeper fragments at the hospital.
2. Prepare a pad to be placed on the wound.



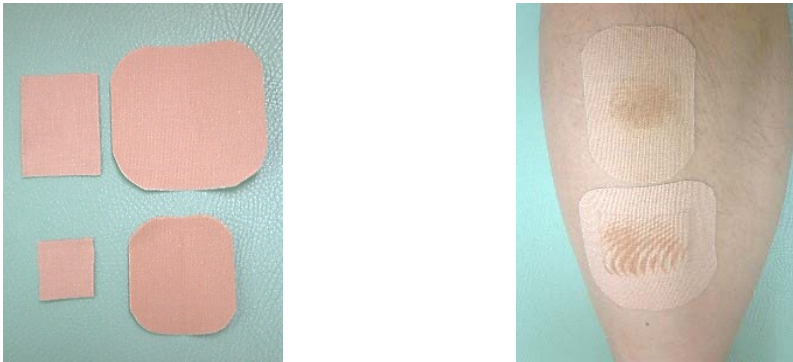
The Kinesio Tape should be cut to a size that completely covers the wound, and folded on itself (two glue surfaces together) to make a pad.

3.



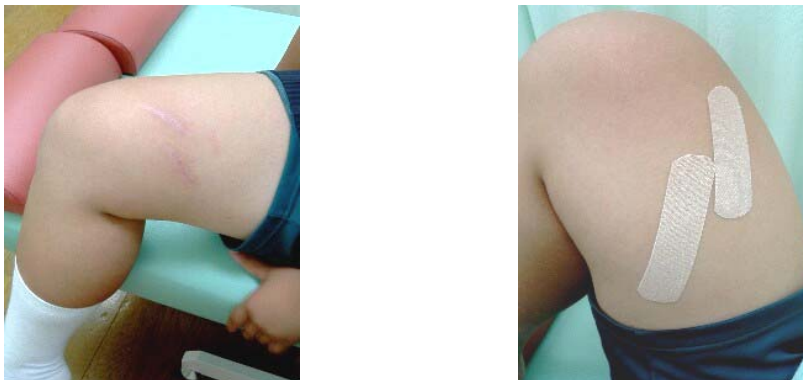The wound and the pad should be moistened well with tap water or deep-sea water, and the pad should be placed on the wound.

4. A Second Kinesio Tape cut to a size that completely covers the pad is then applied to protect the pad.

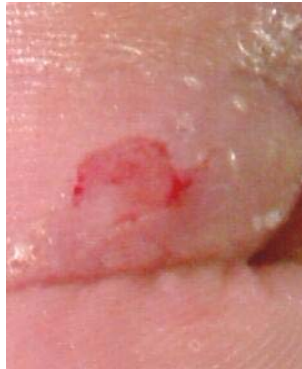

The above procedures should be repeated, but it is not necessary to change it every day. If the Tape is contaminated or nearly peeled, it should be changed. In addition, if it is hygienically affected, it should be changed every day. Thereafter, tap water or deep-sea water should be sprayed to moisten the Kinesio Tape so the wound does not dry out.

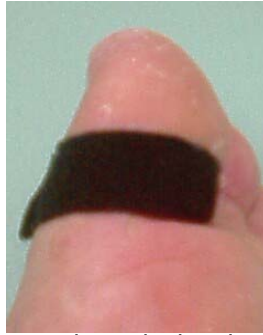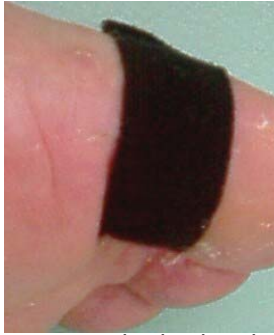5. When the scab has disappeared or the cut skin healed, the pad should be removed, and the Kinesio Tape should be applied directly onto the scar. At this point it is no longer necessary to moisten the tape. The tape should be applied continuously until the scar disappears completely or the patient is no longer concerned about the scar.



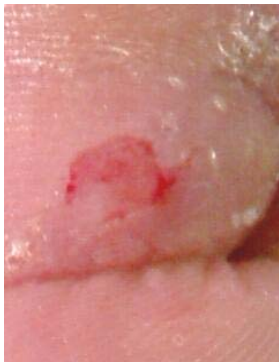I will discuss several cases.
<Abrasion 1>



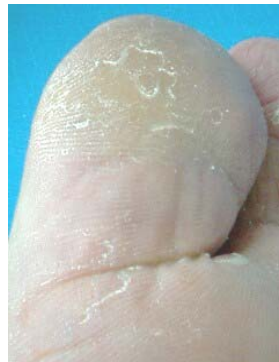A 32-year old man. A wound about 1 cm in length on the left thumb, which was caused by abrasion with the corner of concrete block.



Kinesio Tape was attached using deep-sea water as shown in the photograph.



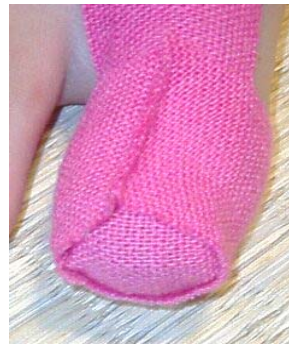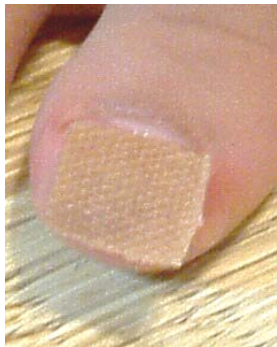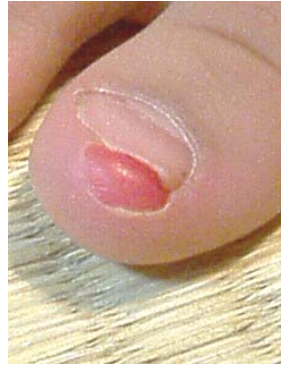The wound at the time of injury



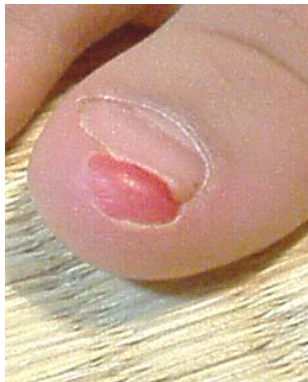The wound after 5 days of treatment.

<Abrasion 2>

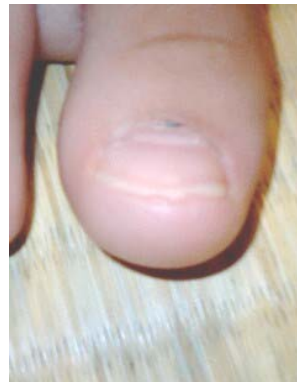A 6-year old girl with a wound in the left thumb. It is about 1 cm in length, and the skin turned over by abrasion with a tatami mat.



Kinesio Tape was attached using deep-sea water as shown in the photograph.

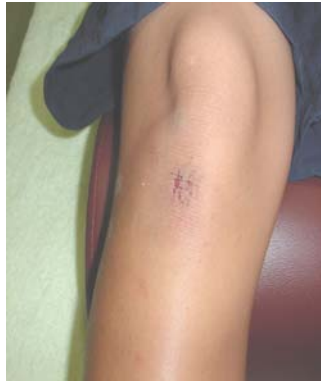

The wound at the time of injury

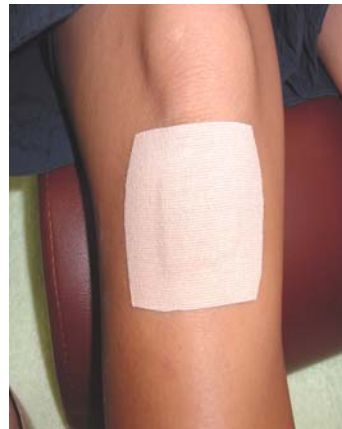
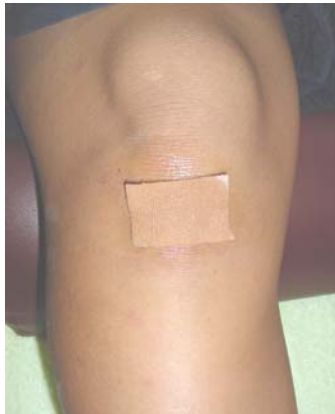
The wound after 1 week of treatment.

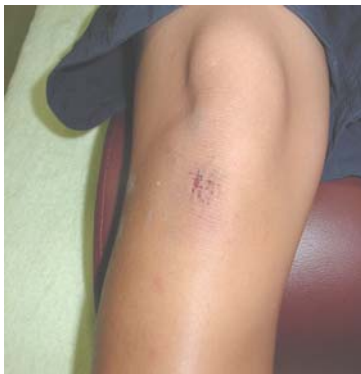<Abrasion 3>



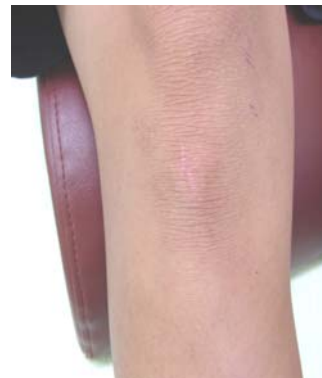A 22-year old woman with a wound about 2 cm in length on the right knee, caused by falling while playing touch football. This photo is the wound 3 days after the injury.



Kinesio Tape was attached using deep-sea water as shown in the photograph.

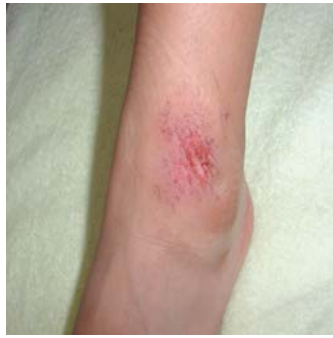

The wound 3 days after the injury

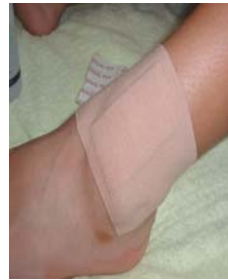
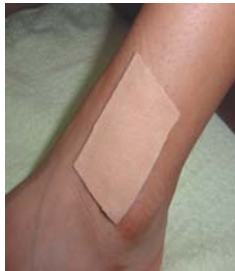
After 1 week of treatment.

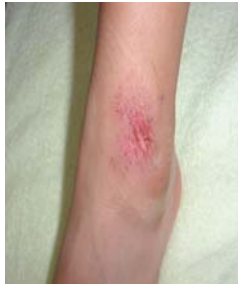<Abrasion 4>



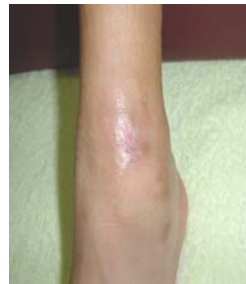A 22-year old woman with a wound about 4 cm in length on the left ankle, caused by falling while playing touch football. It is a moderately deep wound.



Kinesio Tape was attached using deep-sea water as shown in the photograph.



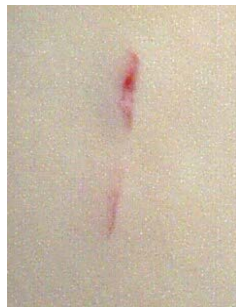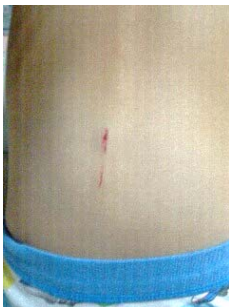The wound at the time of injury



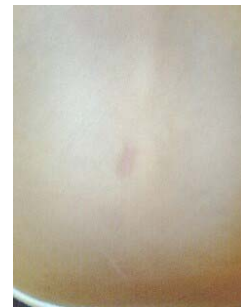The wound after 1 week of treatment.

<Abrasion 5>

A 5-year old boy. A wound caused by abrasion with the corner of a pillar.



These photographs show the dried wound.

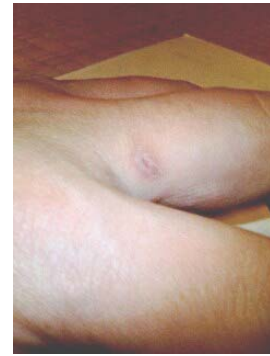

The wound after about 1 month of treatment.
Scar still remains.

<Abrasion 6>

A 30-year old man. A wound caused by scratching with nails.

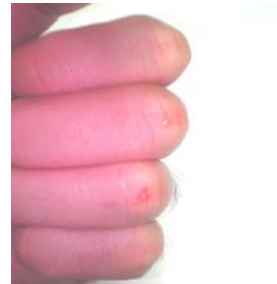This photograph shows the dried wound after about 3 weeks of treatment. Scar still remains.



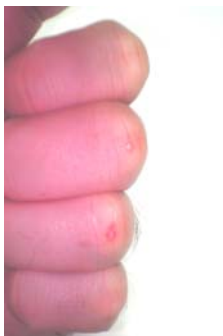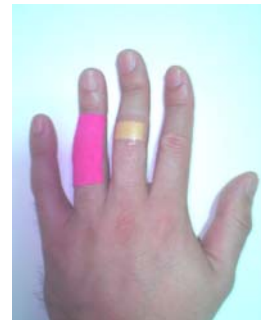<Abrasion 7>

Comparison between Kinesio Tape and adhesive tape was attempted.

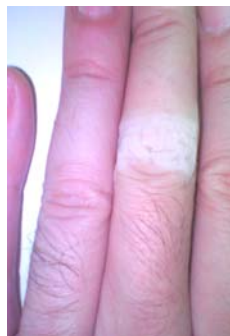A 29-year old man with an abrasive wound. It is about 5 mm in length and localized in the joint between the third and fourth fingers of the left hand and.



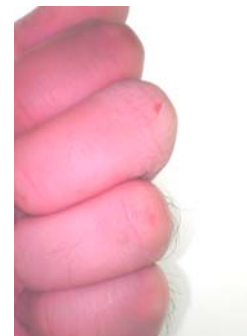Using tap water, Kinesio Tape was attached to the fourth finger, and the adhesive tape was attached to the third finger.



The wound at the time of injury

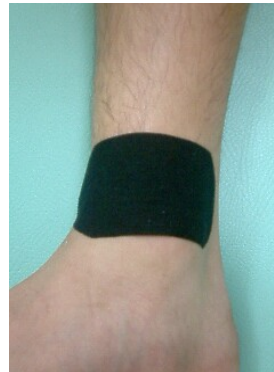
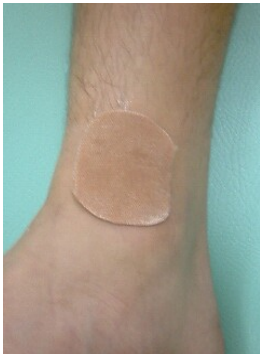
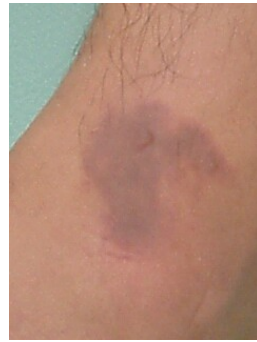The wound after 3 days of treatment. The scar on the fourth finger has nearly disappeared, but the area with the adhesive tape on the third finger became wrinkly, and the scar still remains.

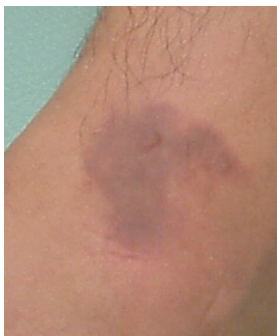

<Frostbite>

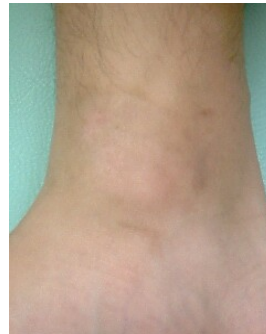A 17-year old man. This wound is considered a second-degree frostbite caused by a cold spray on the right ankle joint. It is about 5 cm in size.



Kinesio Tape was applied using deep-sea water as shown in the photograph.



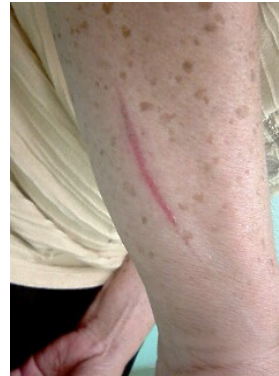The wound at the time of injury



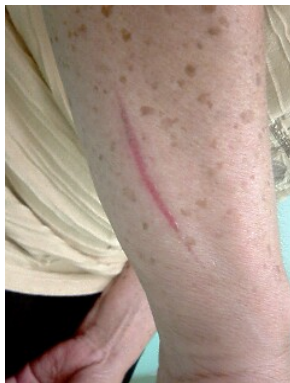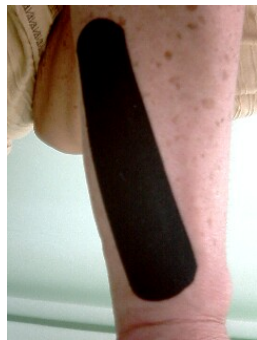The wound after 3 weeks of treatment.

<Burn 1>

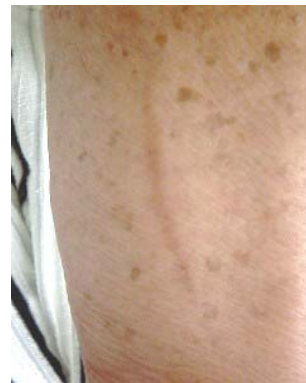A 65-year old woman. This wound is considered a second-degree shallow burn on the right forearm, which was caused by contact with a frying pan. It is about 10 cm in length 3 days after the injury.



Tap water was used.

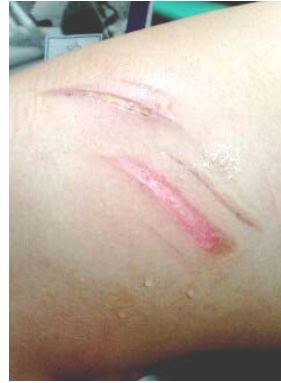
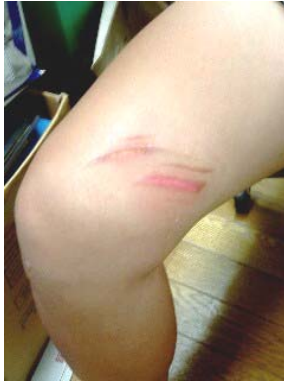
The wound 3 days after the injury

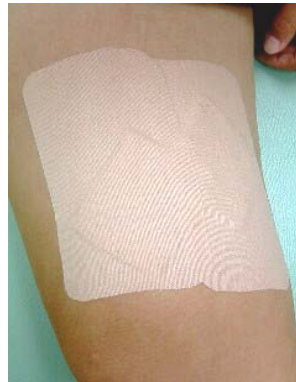
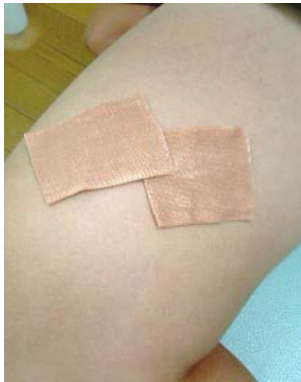
The wound after 1 week of treatment.

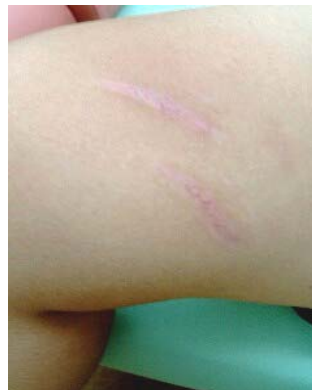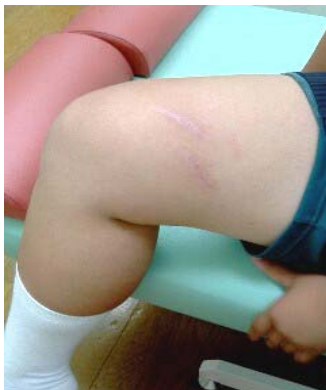<Burn 2>



A 17-year old woman. A burn caused by contact with an iron plate while baking bread. It is considered a second-degree deep burn on the right thigh 4 days after the injury. In this case, the wound is relatively large, and she had a total 4 wounds, with the largest about 8 cm in length and about 1.5 cm in width. I recommended that she go to the hospital because she could not feel the wound and the skin was feeling tightened, but she strongly wished to try this therapeutic method first, so the treatment was started.

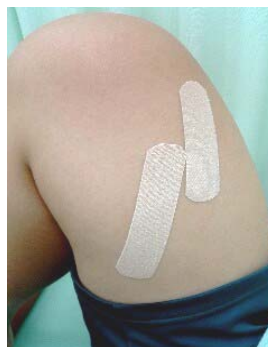

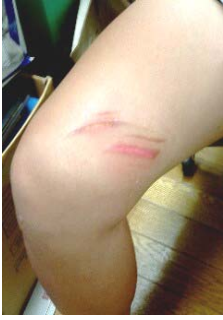Kinesio Tape was applied using deep-sea water as shown in the photograph.



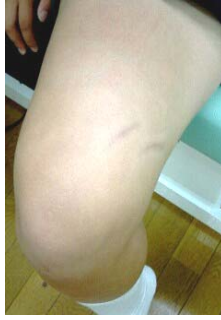The wound after 1 month of treatment. At this point, two smaller wounds have disappeared completely.

Since the scab had disappeared at this point, Kinesio Tape was applied directly onto the scar.

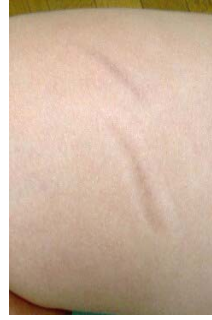



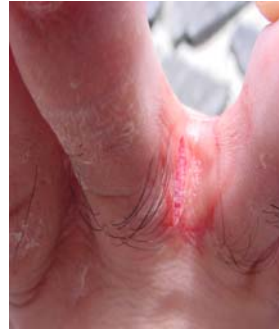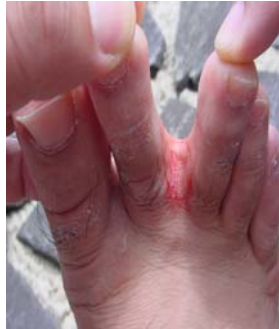The wound 4 days after the injury



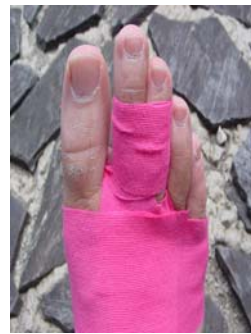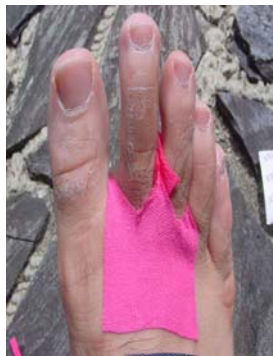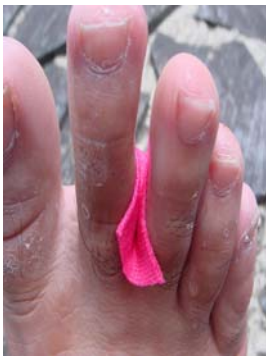After 3 months of treatment. The remaining 2 wounds reduced to about 1/3 of their size at the time of injury, and the irregularity of the wound has disappeared.



<Laceration>

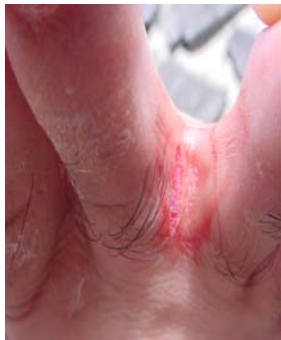

A 32-year old man with a wound caused by clashing into something while swimming and lacerating the skin between the second and the third toes of the right foot.

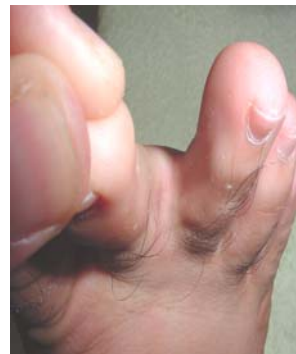

Kinesio Tape was attached using deep-sea water as shown in the photograph.

The wound at the time of injury

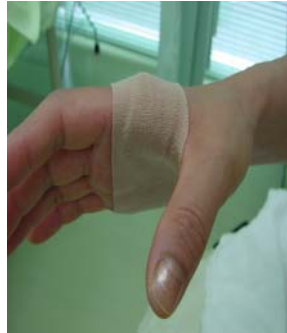
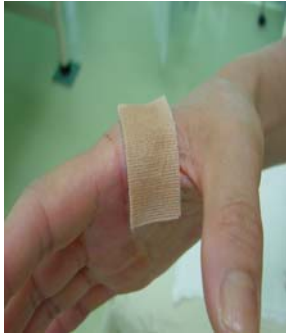
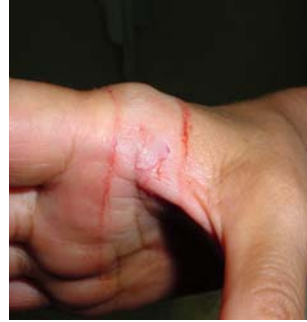The wound after 1 week of treatment

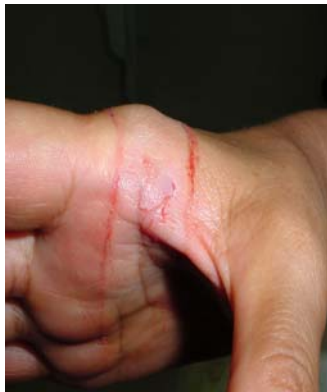

<Cut 1>

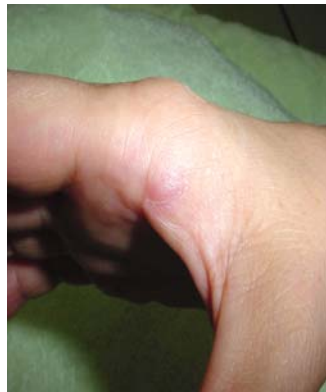A 55-year old woman with a wound about 2 cm in length on the right hand, caused by a broken glass while washing table ware.



Deep-sea water was used.



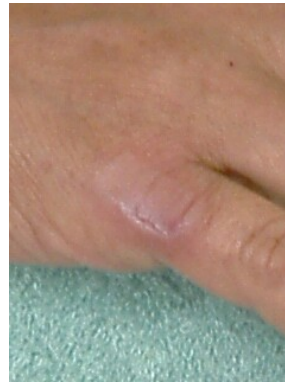The wound at the time of injury



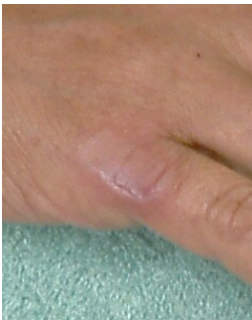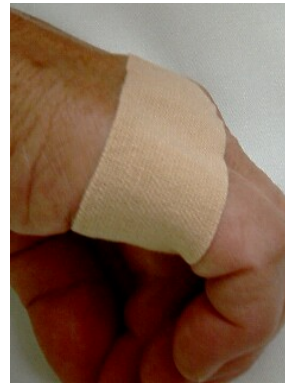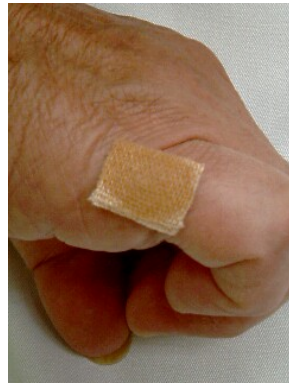The wound after 1 week of treatment.

<Cut 2>

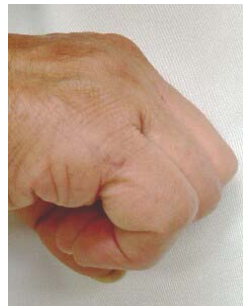A 65-year old woman with a wound about 1 cm in length on the fifth finger of the right hand, caused by a broken glass while washing table ware. The wound 2 days after the injury.



Tap water was used.



The wound 2 days after the injury

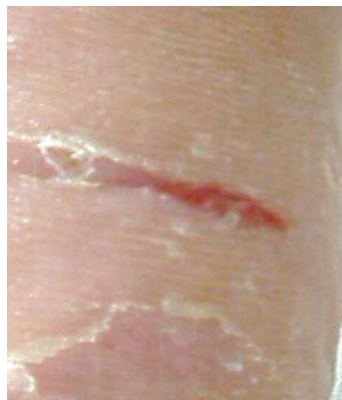

After 1 week of treatment.

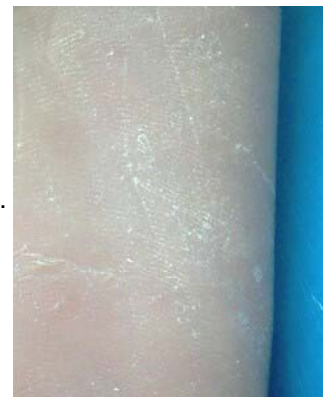<Cut 3>

A 33-year old man with a wound on the sole region on the side of little toe, caused by stepping on something. It is 2 cm in length and a few mm in depth. Tap water was used.

The wound 3 days after the injury



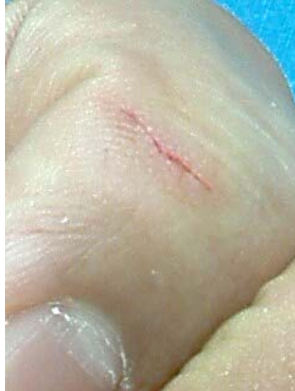After 1 week of treatment.



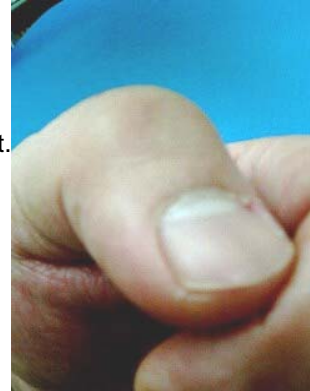
<Cut 4>

A 32-year old man with a paper cut 1 cm in length and 1 mm in depth. Tap water was used.

The wound at the time of injury

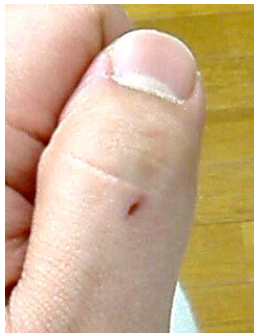

After 1 week of treatment.

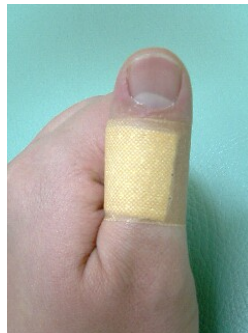

<Cut 5>

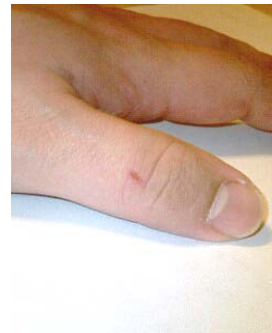A 30-year old man with paper cut, with the skin slightly turned over. It is 3 days after the injury. It was treated with an adhesive tape only without moistening.



The wound 3 days after the injury

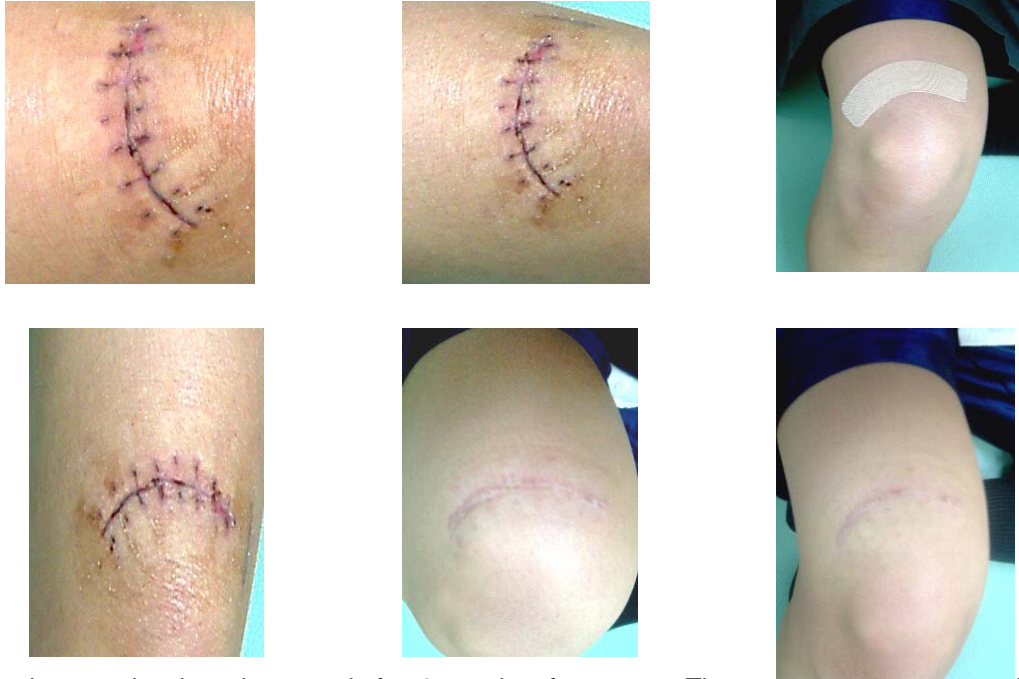


After 3 weeks of treatment. The scar still remains.



<Cut 6>

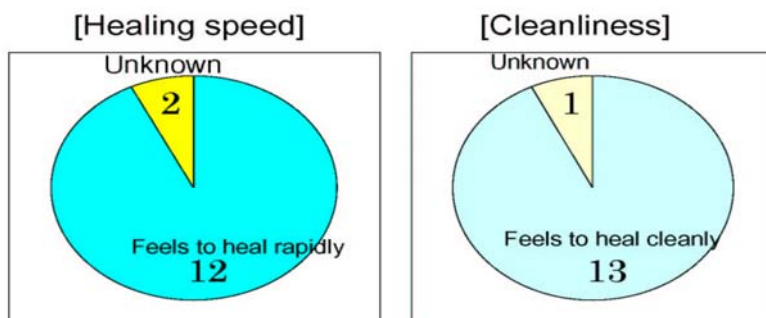
A 16-year old female high school student with a cut caused by falling on a knee. It is about 10 cm in length, and these photographs show the wound 3 days after removal of the suture. Tap water was used until the scab disappeared, and thereafter, Kinesio Tape was applied directly.



These photographs show the wound after 2 months of treatment. The wound was shortened slightly, and the scar from the sutures disappeared gradually.

<Results>

- 1. Water or deep sea water were used on a total 14 cases (including those not shown in photographs).
 - Abrasion in 6 cases
 - Burn (including frostbite) in 3 cases

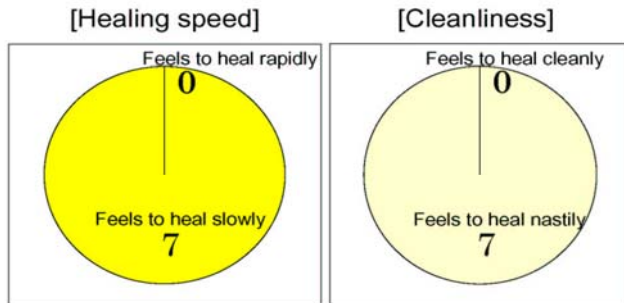


Cut (including laceration) in 5 cases

All the patients answering “unknown” had burns including severe ones and the ones treated continuously.

2. A total of 7 cases of dried wounds

- Abrasion in 4 cases
- Cut in 3 cases



<Discussion>

1. By moistening the pad, the skin cells are more easily regenerated, white blood cells, platelets and cytokines actively accelerate regeneration of the skin, and eschar does not readily form.
2. Since the skin cells regenerated more easily, bacterial infection is reduced.
3. In changing the pad, the scab does not adhere to the pad and peel off forcibly, therefore the cut is not reopened.
4. By applying Kinesio Tape to the scar, the circulation of the blood and lymph fluid under the scar and its surrounding skin is improved, and regeneration of the skin is accelerated.

From the above, it is believed that the natural healing power is maximized, that regeneration of the skin is accelerated and the wounds heal more rapidly, cleanly and with minimal scarring.

Finally, it is considered better to have an examination at the hospital in the case of very large or deep wounds. Since this clinic is an acupuncture and orthopedic clinic, it is impossible to use drugs, but we will use this method for the treatment of skin wounds in the future.